

acoustic microscopy

Lesions in tooth enamel

A section through a human tooth is shown on the next page. The tooth had been extracted from a patient (for orthodontal reasons, not just for this experiment). It was then exposed to an acid environment, to simulate the process of demineralization that leads to the formation of a caries lesion. Finally, it was cut in two longitudinally (i.e. roughly parallel to the growth direction), and one of the exposed surfaces was carefully polished. The area of the lesion was too big to be scanned in one go, and so four images have been mounted in a collage.

In Fig. (a) the polished surface lies at the focus of the lens. The anatomical surface is towards the top of the picture; the region above that is simply mounting towards the top of the picture; the region above that is simply mounting resin.

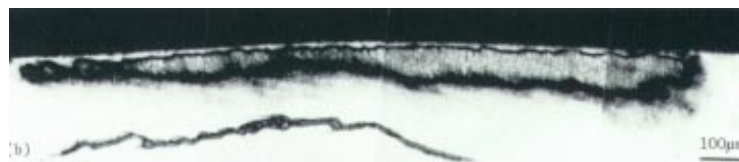
It is possible, to make out the interface between the enamel and the dentine, and also a hazy darkish region in the enamel, Fig. (b) is the same area at the same magnification; the difference is that the specimen has been moved $14\ \mu\text{m}$ towards the lens. Now a great deal more of the structure of the lesion is apparent. At the advancing front of the lesion (the part nearest the dentine), there is a gradation in properties. On the side nearest the anatomical surface the changes are much more abrupt; indeed, there is a region about $20\ \mu\text{m}$ wide that shows uniform contrast similar to that of the healthy enamel away from the lesion. When lesions of this type occur naturally they have a slightly milky appearance due to the way that light is scattered in them, so they are often called white spot lesions. Provided the thin layer of healthy enamel at the surface remains intact, it is possible, for the lesion to recover naturally. It is, therefore, of great interest to study the changes in mechanical properties associated with the formation of the lesion.

acoustic microscopy

Caries lesions in human tooth enamel



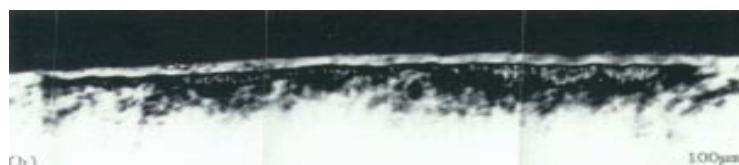- a) A scanning acoustic micrograph of an artificial caries lesion. The lesion was produced by the ten Cate method. The micrograph was taken at the surface, frequency 370MHz



- b) The same lesion as featured in (a), but taken with the microscope at a defocus, $z = -14\mu\text{m}$



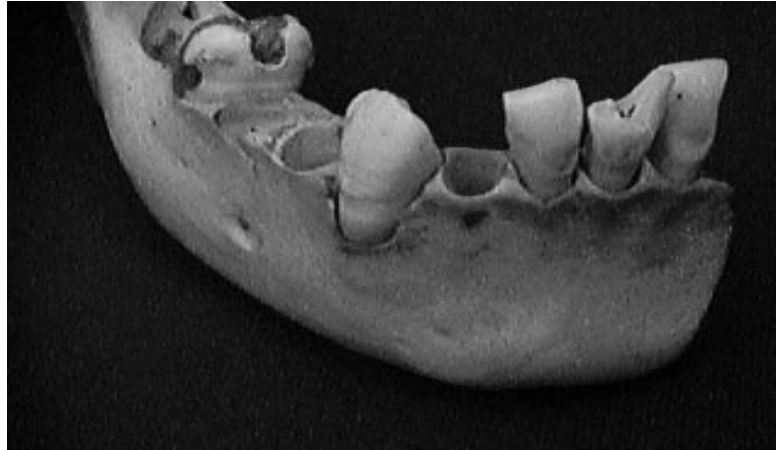- a) A scanning acoustic micrograph of an artificial caries lesion produced by Silverstone gel method. The micrograph was taken at the surface, frequency 370MHz



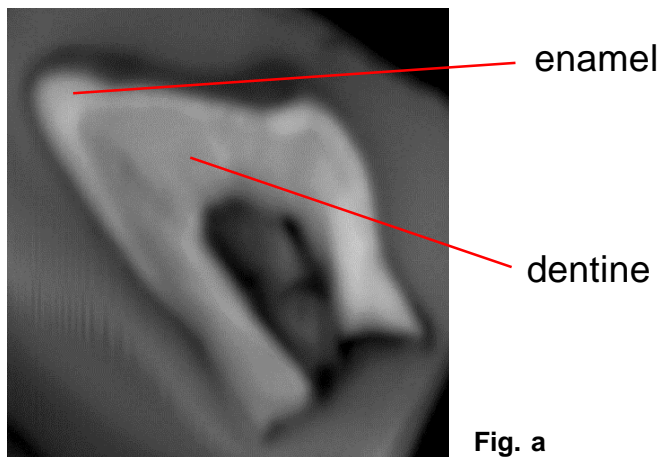
- b) The same lesion as featured in (a), but taken with the microscope at a defocus, $z = -14\mu\text{m}$

acoustic microscopy

Reconstruction of the inner tooth structure



Courtesy of Dr. C. Jørgensen, Denmark



The SAM image is taken with 80MHz. The C-scan and 3D image shows clearly the distinction between the outer enamel (hard) and the inner dentine (softer).

